



THE USE OF SUPPORT ULTRASOUND AS A WORKING TOOL FOR THE PHYSIOTHERAPIST A REVIEW OF THE LITERATURE

■ Collebrusco Luca ¹, Zualdi Luca ²

¹Rehabilitation Unit, National Health Service of Umbria, Perugia, Italy

²Post graduated Physiotherapist, Perugia, Italy

■ **KEYWORDS:** rehabilitative ultrasound imaging, RUSI, biofeedback, ultrasound imaging, physiotherapy.

ABSTRACT

*narrative Review. **Background:** The use of ultrasound to assess muscle morphology and guide rehabilitation decisions has recently developed; this approach has called Rehabilitative Ultrasound Imaging (RUSI). The modern physiotherapist in light of the new legislative regulations, law n.24 of 8 March 2017, law n.3 of 11 January 2018, may have new skills exclusively support use. **Objective:** evaluate the material present in the literature regarding the reliability of the measurement through the ultrasound image for rehabilitation use, the possible use in the functional evaluation and treatment through ultrasound biofeedback and training strategies for the use in the clinical practice with uses, benefits and limitations and skills. **Methods:** Literature searches given in the Medline, PubMed and Pedro databases for the past 20 years. Non-English articles were exclude. The selection of the articles carried out based on the reading of the title, abstract and full text, and the inclusion of related articles. **Results:** The review produced 81 articles, 23 excluded for the title, 14 excluded for abstract. After having read the full test of the 44 remaining articles, 16 excluded because they were not relevant in the discussion of the work, in addition, 7 articles included as related articles, totals of 35 reviewed articles. **Conclusions:** Despite the many difficulties due to the heterogeneity of the studies, from the data that emerged from the review future research, have to examine and validate in more detail the protocols of the RUSI for to create shared training standards, guidelines and good clinical practices.*

INTRODUCTION

In light of the new Law Legislation No. 24 of the 8th March 2017 and the establishment of the Associations for healthcare professionals, due to the Law No. 3 of the 11th January 2018, Rehabilitative Ultrasound Imaging may be an additional tool that physical therapists can employ during assessment and treatment. This specific use of the RUSI, within the duties of physical therapists, is in line with the Law No. 251 of the 10th August 2001. RUSI may help the physical therapists by virtue of the increase of the quality and the safety of the patient treatment. Since the modern physical therapist needs to have a wider and wider knowledge and to share it with the other healthcare professionals, using high-tech tools -which are already employed by other HCPs- can support the management of movement disorders. RUSI practice as a support for the functional assessment and the treatment can only enhance the quality and the safety of the therapy. Other healthcare professionals, such as nurses and midwives (Degree Courses L/SNT1), have been already using non-diagnostic ultrasound imaging, after a standard training and within specific application fields^{1,2}. These HCPs work in synergy with doctors. However, the application of the RUSI in physical therapy still shows some shadow zones. The first studies that the literature reveals about the “Rehabilitative Ultrasound Imaging (RUSI)” date

back to the end of the 80’s^{3,1}. The aim of this study is to review the literature in order to clarify the RUSI reliability and its practice in physical therapy.

METHODS

A single operator has reviewed the literature of the last 20 years, conducting a research of *rehabilitative ultrasound imaging, RUSI, biofeedback, ultrasound imaging, physiotherapy* key terms on Medline, PubMed and Pedro. All the articles linked to the subjects above have been included in the research form. *Inclusion Criteria:* eligibility of the subject, use of ultrasound feedback as an additional tool to the standard treatment, effects on rehabilitation. *Exclusion Criteria:* unsuitable study designs, not available abstracts, not eligible studies, not English language publications.

RESULTS

After the first research, 81 articles had been found; 23 were excluded due to the title and 14 due to the abstract. Once the reviewer had accurately read the full texts of the 44 selected articles, he excluded 16 of them in account of the lack of relevance to the goal of the research. Seven studies among the “*related articles*” were included, therefore 35 studies have been examined. Publications that were not available in English language, studies that lacked abstract and

1 <https://www.fnopi.it/?s=ecografia>.

2 <http://www.fnopo.it/news/master-universitario-di-livello-tecniche-ecografiche-e-c.htm>.

3 Rehabilitative Ultrasound Imaging Symposium: Overview, San Antonio, TX May 8-10, (2006).

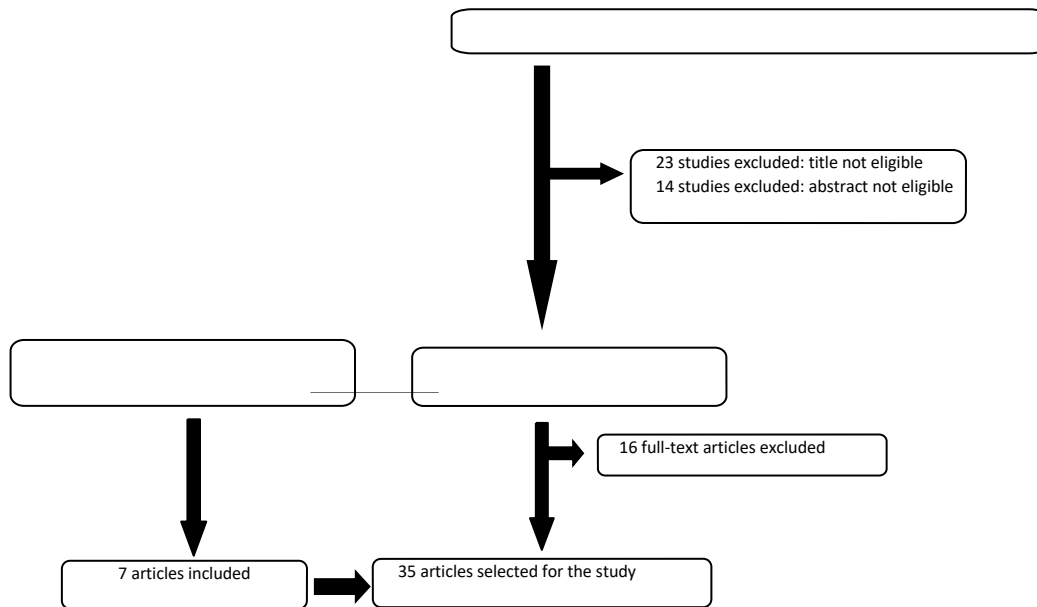


Fig. 1 - Flow Chart of inclusion of studies.

articles that had been published in all of the analysed Databases, were excluded. The 35 reviewed studies are scheduled in a flow chart (figure 1) that shows the selection process of the publications that have been chosen as reference (as summarised in table 1, 2, 3, 4). According to the subject, the references are divided into four categories: reliability of ultrasound imaging measurement (Table 1), functional assessment and treatment through the use of ultrasound imaging (Table 2), practice of ultrasound imaging as an outcome measure (Table 3), specific training for employing RUSI (Table 4).

Reliability of ultrasound imaging measurement (Table no. 1)

O'Sullivan C. et al. (2009)² identified RUSI as a reliable method to measure inferior trapezius muscle thickness. Hebert JJ. et al. (2009)³ showed that most of the highest quality studies state a good intra- and interrater reliability for measurement of trunk and abdominal wall muscles. Lin YJ. et al. (2009)⁴ demonstrated that RUSI is reliable for measurement of thickness of dorsal muscles of the upper cervical spine at rest. Teyhen DS. et al. (2009)⁵ pointed out that ultrasound imaging can seize significant differences in transverse abdominis muscle (TrA) and internal oblique muscle (OI) thickness, lack of balance, and contraction volume increase between healthy people and people who suffer from lumbar-pelvic pain. Bentman S. et al. (2010)⁶ suggested RUSI as an effective tool to measure middle trapezius thickness. Day JM. (2013)⁷ pointed out a good intrarater validity of RUSI for measurement of serratus anterior muscle and inferior trapezius muscle thickness. McGaugh J. Et al. (2011)⁸ deemed that using RUSI may be a reliable way to assess the deep neck flexor muscles thickness. Tablott NR. et al. (2013)⁹ showed a fair interrater reliability for measurement of serratus anterior muscle diameter. Wong AY. et al. (2013)¹⁰ detected a good reliability of RUSI for both static and dynamic functional assessment of multifidus muscle (MF). Schneebeli A. (2014)¹¹ demonstrated a good intrarater and interrater reliability for measurement

of supraspinatus muscle thickness. Temes WC. et al. (2014)¹² revealed a significant interrater and intrarater reliability for assessment of supraspinatus muscle, both passively and actively. Sions JM. (2014)¹³, (2016)¹⁴ demonstrated in his two studies the great reliability of RUSI for measurement of multifidus muscle thickness in young and elderly people with chronic low back pain. Jeong JR. et al. (2016)¹⁵ suggested RUSI as an interrater and intrarater reliable tool to measure romboid muscles thickness.

List of abbreviation: Active straight leg raise (ASLR), Cross-sectional area (CSA), Deep neck flexors (DNF), Internal oblique (IO), Low back pain (LBP), Chronic low back pain (CLBP), Lower trapezius (LT), Lumbar multifidus (LM), Middle trapezius muscle (MT), Nuclear magnetic resonance (NMR), Rehabilitative ultraSound imaging (RUSI), Serratus anterior muscle (SA), Transversus abdominis (TrA).

Functional evaluation and treatment through ultrasound biofeedback (Table 2)

In the works of 2011 Lee NG. et al. (2011)¹⁶ Abdominal Draw-in Manoeuvre (ADIM) training can effectively improve lumbar pelvic stabilisation in adults with functional lumbar instability. Painter EE. et al. (2007)¹⁷ highlights the potential role of RUSI both as a functional assessment tool and as a biofeedback tool in the treatment of deep abdominal muscles and pelvic floor muscles in people with sacroiliac joint mobility disorders and pelvic dysfunction. Teyhen DS. et al. (2007)¹⁸ RUSI can be an emerging method with the potential to improve rehabilitative care and to search for some dysfunctional sub-classifications of lumbar and pelvic pain. Kiesel KB. et al. (2008)¹⁹ preliminary data are provided indicating how RUSI can be used to measure changes in muscle activation of Tra and MF linked to trunk pain. Kiesel KB. et al. (2007)²⁰ The RUSI compared with the electromyographic examination (EMG) is a valid and potentially useful method to measure the thickness change of the MF muscle. Hides JA. et al. (2008)²¹ the work provides us as a lumbar stabilization exercise program including

<i>STUDY DESIGN</i>	<i>PURPOSE</i>	<i>METHODS</i>	<i>CONCLUSIONS</i>
O'Sullivan C. et al., 2009 Cross-sectional study	Comparison between rehabilitative ultrasound imaging (RUSI) and nuclear magnetic resonance (NMR) to measure inferior trapezius (LT) muscle thickness.	The patient is supine. At first, the rater tests C6, T1, T5, T8 vertebral sections with NMR. Right after, the assessment repeated using RUSI.	RUSI is an effective tool to measure LT muscle thickness.
Hebert JJ. et al., 2009 Systematic review	Review of the literature on the reliability of RUSI for abdominal and lumbar muscles morphology assessment.	The original articles, that show the RUSI quantitative measures, have been identified. Reliable data and methodological quality (assessed by two separate raters) are extracted.	Most of the highest quality studies point out a good interrater and intrarater reliability for assessment of trunk and abdominal muscles with RUSI.
Lin YJ. et al., 2009 Clinical study	Examination of intrarater and interrater reliability to measure sub-occipital and dorsal-cervical muscles thickness at rest and sub-occipital muscles thickness as activating up to the 50% of active isometric contraction, while performing an upper cervical extension.	Ten healthy people, from 21 to 30 years old, without neither neck pain or headache, participated in this study. Dorsal-cervical muscles are assessed with RUSI both at rest and at 50% of active isometric contraction while the patient, sitting, is performing an upper cervical extension. Pectoralis major, posterior rectus capitis posterior major, oblique capitis superior semispinalis, splenius capitis have been assessed. After a 10-minute-rest, the same rater measures these muscles once again.	Using the RUSI to measure dorsal-cervical muscles thickness at rest and at 50% effort during an upper cervical extension, is reliable.
Teyhen DS. et al., 2009 Cross-sectional study	Differences, if any, in transversus abdominis (TrA) and internal oblique muscular thickness as performing an active straight leg raise test (ASLR) between people with and without low back pain.	RUSI is employed to compare the percentage variation of TrA and IO at rest, within 5 and 10 seconds after ASRL test. The measurements are bilateral and concurrent.	This study demonstrates significant differences in TrA and IO muscles thickness, lack of balance, and contraction volume increase between healthy people and people who suffer from lumbar-pelvic pain.
Bentman S. et al., 2010 Cross-sectional study	Describes how RUSI can be a method to measure the thickness of the middle trapezius muscle (MT).	16 asymptomatic subjects aged between 20 and 41 years old. The thickness of the MT is measured by three evaluators: one carries out two measurements at a distance of two days, the other two carry out the two measurements on the second day.	The RUSI Method can be used reliably to measure the muscle thickness of MT muscle.
Day JM. et al., 2013 Cross-sectional study	As the RUSI establishes the reliability for measuring the thickness of the muscles stabilizers of the scapula, as well as examines the change of the thickness of the stabilizers of the scapula during contraction in different workloads.	14 subjects, 7 males with average age of 27 years old and 7 females with average age of 26 years old. Measurements were taken using RUSI in 11 conditions: 1 rest and 10 with different progressive loads for LT and serratus anterior (SA) respectively. The procedures were repeated the following week.	It has verified good intra-examiner reliability for SA and LT muscle thickness measurements.

McGaugh J. et al., 2011 Cross-sectional study	It examines the reliability of RUSI to measure the size of the deep neck flexor muscles (DNF).	DNF muscle thickness is measured in a sample of 8 women aged from 33 to 11 years old.	The RUSI method could be used to reliably assess the thickness of DNF muscles.
Tablott NR. et al., 2013 Cross-sectional study	It determines the reliability of SA thickness measurements through the RUSI method.	The sample is composed of 20 healthy subjects. The measurements take place with the subject seated and the arm flexed to 120°. The image of the SA muscle is made when the hand grabs a weight of 1.4 kg approximately. On the first day of the exam the images were repeated three times for each condition by the same examiner. On the second day, examiner 1 and examiner 2 repeated the exam.	The RUSI method demonstrates reasonable intra-examiner reliability in measuring the muscle diameter of the SA muscle.
Wong AY. et al., 2013 Cross-sectional study	It compares the reliability of RUSI in quantifying the thickness of the LM at rest and in contraction with both static and dynamic images, as well as comparing the accuracy of the measurements carried out.	27 volunteers are examined (13 without LBP and 14 with LBP), three measurements are made on static and dynamic images via video clips with RUSI. In two sessions, four days apart.	The RUSI method has good reliability for the static and dynamic functional evaluation of the LM.
Schneebeil A. et al., 2014 Cross-sectional study	It examines intra and inter-examiner reliability of the cross sectional area (CSA) measurements of the supraspinatus muscle using RUSI.	25 healthy subjects are examined, two physiotherapists measure through images in B-mode mode, the CSA of the supraspinatus muscle.	It has a good intra and inter-examiner reliability for the measurement of the thickness of the supraspinatus muscle with RUSI.
Temes WC. et al., 2014 Cross-sectional study	It determines the validity and reliability of the measurements obtained by using the RUSI for the evaluation of the supraspinatus muscle at rest and during contraction.	15 asymptomatic subjects aged from 30 to 49 years old. Ultrasound images of the supraspinatus muscle are collected by three physiotherapists on two separate days. The supraspinatus muscle is measured at rest and contracted with a load of 0.9 kg with the arm positioned at 45° of abduction in the scapular plane.	In the evaluation of supraspinatus muscle thickness at rest and in contraction with RUSI it is demonstrated a high intra- and inter- examiner reliability.
Sions JM. et al., 2016 Cross-sectional study	It evaluates intra and inter-examiner reliability in RUSI measurement of LM thickness between older adults (60-85 years of age) and younger adults (18-40 years of age) with chronic low back pain (CLBP).	30 old and 31 young adults are examined, two examiners assess the thickness of the lumbar LM at rest and during a contralateral lifting of the lower limb with extended knee.	It shows that there is an excellent reliability for the measurement of LM thickness in young and older adults with chronic low back pain.
Jeong JR. et al., 2016 Clinical case	It evaluates the intra and inter-examiner reliability of RUSI for measuring the thickness of rhomboid muscles.	24 young adults (8 men, 16 women) with an average age of 24 years old, without a history of neck, shoulder or arm pain. The images of the rhomboid muscles were obtained in the resting position and with shoulder in abduction of 90° through RUSI with linear multifrequency transducer (5-7 MHz).	It shows that there is a good intra and inter-examiner reliability of muscle thickness measurements of rhomboid muscles with RUSI.

Tab. 1- INCLUDED ARTICLES: RELIABILITY OF ULTRASOUND IMAGING MEASUREMENT.

voluntary contraction of MF muscle, TrA, and pelvic floor through ultrasound feedback with RUSI in young athletes with lumbar pain leads both to a reduction in pain levels and an increase in cross-section area (CSA) of MF muscle, although an explanation cause effect is not possible.

The use of the ultrasound imaging as an outcome (Table 3)

In the work of Pressler JF. et al. (2006)²² a physiotherapist, newly trained in the use of ultrasound, obtained reasonable intra-operator reliability in imaging the MF muscle in the area of the first sacral S1 vertebra. Brenner AK. et al. (2007)²³ the use of RUSI offers a convenient method for investigating and documenting how the MF muscle is affected by spinal manipulation. Hides JA. et al. (2007)²⁴ the physiotherapist, trained in RUSI, showed variable reliability in assessing the anterolateral abdominal wall muscles during ADIM while the inexperienced physiotherapist showed less reliability during the measurement. Raney NH. et al. (2007)²⁵ the use of the RUSI method applied to the study of the behaviour of core stability muscles after spinal manipulation has allowed us to see how there is an increase in the

thickness of the TrA muscle during ADIM immediately after spinal manipulation as well as a decrease in post-manipulation. of the thickness of the TrA muscle at rest. Herbert WJ. et al. (2008)²⁶ maintenance of the motor task in isometric MF muscle recruitment was significantly achieved with ultrasound feedback rather without ultrasound feedback. Sweeney N. et al. (2014)²⁷ the results obtained through the RUSI on the activation of the MF muscle in the prone position by raising the opposite upper limb (OUL) and in standing position in individuals with unilateral chronic lumbar pain (UCLP) and in healthy people provide us evidence of the contractile behaviour of the MF muscle. Individuals with unilateral UCLP showed a greater percentage of thickness change than the control group. Hosseinifar M. et al. (2015)²⁸ the trans-abdominal RUSI method is reliable for quantifying the contraction of pelvic floor muscles in healthy subjects, as well as for measuring the SAT of the MF muscles, and the thickness of the MF muscles at rest and during functional tasks in healthy subjects. Jopowicz R. et al. (2017)²⁹ the RUSI shows a good efficacy in the treatment through ultrasound biofeedback in lumbar pain, as well as in the rehabilitation of the shoulder and knee in the postoperative improvement for tendon problems.

<i>STUDY DESIGN</i>	<i>PURPOSE</i>	<i>METHODS</i>	<i>CONCLUSIONS</i>
Lee NG. et al., 2011 Case series	Determines the effect of a new abdominal draw-in manoeuvre (ADIM) training in subjects with "core instability".	20 young people with an average age of 24 years old are examined, with "core instability". The TrA, IO, EO muscles are subjected to a training through an ADIM protocol. The TrA, IO, EO muscles are evaluated through RUSI and a study of EMG studies.	The ADIM training program can effectively improve lumbar pelvic stabilisation in adults with functional lumbar instability.
Painter EE. et al., 2007 Clinical study	Check if changes in neuromuscular control of TrA and pelvic floor muscles (PFM) can contribute to sacroiliac joint (SIJ) pain and stress urinary incontinence.	A 35 years old woman with pain since 6 weeks in the left buttock area and stress urinary incontinence since 4 years is examined. RUSI is used to integrate the functional evaluation process, to detect motor control of TrA and PFM through biofeedback during rehabilitation.	The work highlights the potential role of RUSI both as a functional assessment tool and as a biofeedback tool in the treatment of deep abdominal muscles and pelvic floor muscles in people with SIJ mobility disorders and pelvic dysfunction.
Teyhen DS. et al., 2007 Case series	Provides an overview on the use of RUSI for the evaluation and treatment of abdominal muscles in subjects with low back pain (LBP).	RUSI is used to evaluate and improve motor learning by providing feedback to the patient in an effort to improve LM and TrA activation.	RUSI can be an emerging method with the potential to improve rehabilitative care and to search for some dysfunctional sub-classifications of lumbar and pelvic pain.
Kiesel KB. et al., 2008 Cross-sectional study	The study evaluates changes in muscle activation of LM through RUSI after induced pain.	7 healthy subjects with an average age of 29 years old are examined. It is used the ADIM to activate the TrA and a series of activities using the lifting of the upper limbs in order to activate LM muscle. The pain was induced by injecting 5% hypertonic saline into the longissimus muscle, next to the LM at the level of the vertebral segment L4.	Preliminary data are provided indicating how RUSI can be used to measure changes in muscle activation of TrA and LM muscles related to trunk pain.

<p>Kiesel KB. et al., 2007 Cross-sectional study</p>	<p>Compare the reliability of RUSI with EMG, to determine the variation of LM thickness and in healthy subjects.</p>	<p>5 healthy subjects are examined with RUSI and EMG in the L4 vertebral segment at the LM level. EMG and RUSI data are collected simultaneously, while subjects perform increasingly demanding active motor tasks.</p>	<p>The RUSI compared with the EMG exam is a valid and potentially useful method to measure the thickness change of the LM muscle.</p>
<p>Hides JA. et al., 2008 Case series</p>	<p>It documents the effect of a lumbar stabilization exercise program for professional cricketers with and without LBP.</p>	<p>26 athletes were evaluated, 10 with LBP and 16 without LBP. The lumbar stabilization program consists in the voluntary contraction of the TrA and the PFM's in progressive activity with and without load providing in real time an ultrasound feedback with the RUSI for the measurement of the CSA of the LM in four vertebral level L2,L3,L4,L5.</p>	<p>The work shows that in young athletes with LBP after administration of the program monitored via ultrasound feedback there is a significant reduction of lumbar pain and an increase of the CSA of the LM muscle.</p>

Tab. 2 INCLUDED ARTICLES: FUNCTIONAL EVALUATION AND TREATMENT THROUGH ECOGRAPHIC BIOFEEDBACK.

List of abbreviations: Abdominal draw-in manœuvre (ADIM), Cross-sectional area (CSA), Electromyography (EMG), External oblique (EO), Internal oblique (IO), Low back pain (LBP), Chronic low back pain (CLBP), Lum

<i>STUDY DESIGN</i>	<i>PURPOSE</i>	<i>METHODS</i>	<i>CONCLUSIONS</i>
<p>Pressler JF. et al., 2006 Cross-sectional study</p>	<p>Estimates the intra-operator reliability and error of a physiotherapist after a short course of ultrasound imaging of bilateral LM CSA measurement at the S1 vertebral segment.</p>	<p>30 healthy women with an average age of 23 years has been evaluated. Patients assume the prone position to evaluate the CSA of the LM in the vertebral area S1. Having found the area through the ultrasound probe, the patient is asked to raise the contralateral leg with the knee extended about 2.5 cm away from the table.</p>	<p>A physiotherapist without much experience in ultrasound imaging but with only a short training has obtained a reasonable intra-operator reliability in evaluating the CSA of the LM at the level of the vertebral segment S1.</p>
<p>Brenner AK. et al., 2007 Clinical study</p>	<p>It investigates how RUSI can be a useful tool in evaluating the neuromuscular behaviour of the LM of the vertebral tract involved in vertebral manipulation (HVLA).</p>	<p>A 33-year-old man with a 21-year history of LBP undergoes HVLA manipulation in the lumbar spine. The study of the image of the LM is carried out in the vertebral tract of L4-5 and L5-S1 both in the pre-manipulative phase and immediately after and one day after HVLA.</p>	<p>RUSI is a useful method for investigating and documenting how the activity of the LM is influenced by spinal HVLA.</p>
<p>Hides JA. et al., 2007 Cross-sectional study</p>	<p>Examines the reliability of a physiotherapist with 8 hours of training on RUSI, for the dysfunctional assessment of the abdominal muscles through the use of the ultrasound image.</p>	<p>19 subjects (11 females, 8 males) with no history of LBP were evaluated. RUSI is used to assess IO thickness and TrA at rest and in contraction during a supine ADIM. 3 measurements of the same image are performed on 3 separate ultrasound images for 2 days.</p>	<p>The physiotherapist with a RUSI training shows variable reliability in assessing the muscles of the anterolateral abdominal wall during ADIM while the inexperienced physiotherapist shows less reliability during the measurement.</p>

Raney NH. et al., 2007 Case series	Through the RUSI method it is observed how the effect of HVLA at the level of the lumbar vertebral segments can lead to changes in thickness of the TrA and IO muscle.	9 patients were examined (5 females, 4 males) aged 18 to 53 years with symptoms of LBP for less than 16 days. Measurements were taken before and immediately after spinal HVLA. The thickness of the TrA and IO muscle is assessed with the patient at rest and during ADIM monitored in real time by RUSI.	The use of the RUSI method applied to the study of the behavior of the “core stability” muscles after spinal HVLA allows us to see how there is an increase in the thickness of the TrA muscle during ADIM immediately after HVLA. The work provides us with preliminary evidence to suggest that HVLA can affect muscle behaviour
Herbert WJ. et al., 2008 randomized controlled study	How the use of ultrasound feedback with the RUSI can influence a motor learning program for the activation of the LM muscle.	30 subjects without LBP are examined, they were randomly assigned to a group that uses real-time ultrasound image feedback but first performed the activity program under operator supervision and to a group that uses only image feedback real-time ultrasound while activities are taking place. The protocol is eight training sessions for four weeks. The data were collected in the first week and one month after surgery.	The use of ultrasound feedback with the activities previously supervised before the session show significant values in the maintenance of the motor task and in the isometric recruitment of the LM muscle compared to the other group.
Sweeney N. et al., 2014 case-control study	The work aims to determine differences in the resting and contracting thickness of the LM muscle in individuals with unilateral CLBP compared to a control group.	20 participants were evaluated by RUSI, 10 with unilateral CLBP (mean age 26 years) and 10 without CLBP (unilateral mean age 32 years). Two positions are taken: the prone and the erect position to investigate the muscular behaviour of the LM both at rest and in contraction. To contract the LM muscle, an elevation of the contralateral arm (CAL) to the studied LM is required.	The results obtained through the RUSI on the activation of the LM in prone position and in standing position with and without CAL in individuals with unilateral CLBP and without CLBP provide us with evidence of the contractile behaviour of the LM. Unilateral CLBP individuals showed a higher percentage of thickness variation than the control group.
Hosseinifar M. et al., 2015 Cross-sectional study	Evaluates the intra-operative reliability of RUSI in the trans-abdominal measurement of the CSA of the LM muscle, as well as the diameter of the bladder wall.	A single group of 15 patients without LBP with a mean age of 27 years was evaluated. The physiotherapist checks the CSA of the LM at rest and in contraction as well as the diameter of the bladder at rest and the contraction of the PFM.	The trans-abdominal RUSI method is reliable for quantifying PFM contraction, as well as for measuring CSA and LM thickness at rest and during functional tasks in subjects without LBP.
Jopowicz R. et al., 2017 systematic review	Investigate all possible uses of RUSI.	To research the current uses of musculoskeletal ultrasound in rehabilitation through a literature search on basic dates such as: PubMed, Embase, Database ProQuest, Scopus and Web of Science.	RUSI shows good efficacy in treatment by ultrasound biofeedback in LBP, as well as in shoulder and knee rehabilitation and in post-operative improvement in tendon pathologies.

Tab. 3 INCLUDED ARTICLES: THE USE OF ULTRASOUND IMAGING AS AN OUTCOME.

List of abbreviations:: Abdominal drawing in manœuvre (ADIM), Contralateral arm lift (CAL), Cross-sectional area (CSA), High velocity low amplitude (HVLA), Low back pain (LBP), Low back pain chronic (CLBP), Lumbar multifidus (LM), Pelvic floor muscles (PFM), Rehabilitative ultraSound imaging (RUSI), Transversus abdominis (TrA).

Specific training for the use of the RUSI method (Table 4)

In his studies Fernandez-Lao C. et al. (2016)³⁰ suggest the effectiveness of an internet-based training program as a supplement to traditional training for the development of skills in ultrasound and palpation of the shoulder region in undergraduate physiotherapy students. Collebrusco L. et al. (2017)³¹ RUSI can be a reliable method to measure and study the movement of the rotator cuff, and the passage area under the acromial during the contraction of the supraspinatus. Moreover, RUSI seems to be reliable also in specific cases of motor control disorders, observing in real time the behaviour of the musculature that stabilizes the scapula through ultrasound feedback during the activation of the stabilizing muscles of the shoulder. Collebrusco L. et al. (2017)³² Further studies are needed to validate a standardized diagnostic procedure and the conservative rehabilitation program for

lumbar spinal stenosis, the treatment can be aided by ultrasound feedback with RUSI. Doorbar-Baptist S. et al. (2017)³³ RUSI can be used reliably to evaluate pelvic floor motor control in men with prostate cancer. Gray JM. Gray JM. et al. (2017)³⁴ Results suggest that ultrasound training for rehabilitation practitioners requires skills development at multiple levels. Hayward SA. et al. (2018)³⁵ The use of thoracic ultrasound by physiotherapists is an emerging area for both diaphragm and pulmonary functional evaluation, and potential use in rehabilitation. Calvo-Lobo C. et al. (2019)³⁶ RUSI made it possible to verify that the diaphragm muscle thickness is reduced in athletes with lower back pain compared to athletes without lower back pain. Abuin-Porras V. et al. (2020)³⁷ RUSI can be a useful method for activating the TrA muscle and the OI muscle, allowing to see its thickness increase significantly after a forceful exhalation compared to the normal exhalation position.

STUDY DESIGN	OBJECTIVES	METHODS	CONCLUSION
Fernandez-Lao C. et al., 2016 RCT	The study investigates how learning in m-learning as a supplement to the traditional frontal method can be better for physiotherapy students in the acquisition of palpatory skills and ultrasound imaging of the shoulder girdle.	49 students were recruited randomly distributed in two groups: experimental n. 25 individuals with an average age of 21, with free access to the m-learning program and the other to control n. 24 individuals with an average age of 19, through traditional training.	The work suggests that an m-learning teaching program in addition to traditional education for the development of skills in ultrasound and palpation of the shoulder region in undergraduate physiotherapy students is more effective, but not significant.
Collebrusco L. et al., 2017 Studio trasversale	How RUSI can help in functional assessment and treatment of shoulder impingement syndrome (SIS).	Various measurements are taken from the literature through the ultrasound image in B-mode and real-time mode with a multifrequency linear probe from 5 to 10 MHz (length 50 mm) for the structures responsible for the SIS.	RUSI can be a reliable method to measure and study the movement of the rotator cuff, and the passage area under the acromial during contraction of the supraspinatus muscle, as well as in specific cases of motor control disorders, observing the behaviour in real time. Possible ultrasound feedback in the treatment of the stabilizing muscles of the scapula.
Collebrusco L. et al., 2017 systematic review	Evidence-based treatment options that may be useful for improving the quality of life of patients with lumbar spinal canal stenosis (LSS) were analysed.	Different manual techniques are taken into consideration that include both HVLA / mobilization, therapeutic exercise, patient educational intervention together with a walking rehabilitation program, but also the use of ultrasound biofeedback with RUSI, to allow improve neuromuscular control of the "core stability"	Further studies are needed to validate the standardized diagnostic procedure and conservative rehabilitation program of LSS as well as treatment supported in part by ultrasound feedback of the abdominal regional complex through RUSI.
Doorbar-Baptist S. et al., 2017 Case series	It assesses both the motor control of PFMs in men with prostate cancer and the reliability of the physiotherapist to perform the examination with RUSI.	n. 91 men has been examined, diagnosed with prostate cancer and loss of PFM motor skills. During the proposed PFM exercise protocol, execution is monitored by trans abdominal ultrasound biofeedback.	RUSI can be used reliably to assess motor control of PFM in men with prostate cancer.

Gray JM. et al., 2017 Cross sectional study	It examines the NON-medical experiences of the processes of formation and integration of musculoskeletal ultrasound in the field of rehabilitation.	The skills of two occupational therapists in the areas: technical, procedural and analytical are assessed with three practical considerations: understanding the images within the dynamics of rehabilitation, grasping the nuances of interprofessional care, and the implications for post-professional training.	Training in ultrasound for rehabilitation practitioners requires skill development and more outline of the complexity of the practice.
Hayward SA. et al., 2018 Systematic review	Gain an understanding of the emerging evidence on the physiotherapist's use of chest ultrasound (TUS) to inform research and clinical practice.	It is to examine and present a broad overview of the emerging evidence available regardless of quality as well as identify gaps, common use and clarify key concepts on the use of TUS, through a search in the Cochrane database, EPPI center, PROSPERO, Medline, CINAHL, AMED, EMBASE, HMIC, and BNI.	The use of TUS by physiotherapists is an emerging method and may have a potential positive impact in rehabilitation for both diaphragm and pulmonary functional evaluation.
Calvo-Lobo C. et al., 2019 Case control study	Compare the thickness and excursion of the diaphragm in athletes with and without lower back pain (LLP).	40 athletes with an average of 24 years of age with and without LPP were evaluated. The thickness and excursion of the diaphragm (cm) during respiratory activity (maximum inspiration, maximum expiration and the difference) was examined through the ultrasound image.	The methodology applied with the RUSI allows to verify how athletes with LBP present the diaphragm muscle reduced in thickness compared to athletes without LBP in a statistically significant way.
Abuin-Porras V. et al., 2020 Cross-sectional study	quantifies and compares the thickness of the TrA, IO and EO muscle, at rest, through the use of an expiratory insufflator (EFCD), or the ADIM through the use of the RUS	21 healthy women with an average age of 29 years were examined. Three consecutive measurements of the ultrasound images are carried out with the RUSI of the TrA, IO, EO, at rest, at the end of ADIM and at the end of EFCD.	There are statistically significant differences in the increase in thickness of the TrA and IO when using the EFCD and ADIM compared to the resting condition. In addition, the TrA, at the end of the EFCD there is a statistically significant difference compared to the ADIM. Therefore EFCD can be a useful method for activating the TrA muscle.

Tab. 4 INCLUDED ARTICLES: SPECIFIC TRAINING FOR THE USE OF THE RUSI METHOD.

list of abbreviations: Abdominal drawing in manœuvre (ADIM), Diagnostic thoracic ultrasound (TUS), Expiratory flow control device (EFCD), External oblique (EO), Internal oblique (IO), Low back Pain (LBP), Lumbar spinal stenosis (LSS), Lumbopelvic pain (LPP), Pelvic floor muscles (PFM), Rehabilitative ultraSound imaging (RUSI), Shoulder impingement syndrome (SIS), Transversus abdominis (TrA)

DISCUSSION

The data emerging from the review of the literature reveals that RUSI refers to a set of procedures created to assess the morphology and the function of muscles and related soft tissue during exercise and motor activity³⁸ with a good reliability of image measurements. This result has been found out investigating the muscles of the trunk and the abdominal wall³, as well as in the stabilizing muscles of the scapula: upper, middle, lower trapezius and serratus anterior and the muscles of the rotator cuff^{6,7,9,15}. RUSI can be used as a support both in functional assessment and treatment

(as a biofeedback) for the pelvic floor disorders and the related low back pain. Literature reveals that some types of measurement through standardized and reliable procedures could be suggested in daily rehabilitation practice, for instance, the assessment of changes in thickness of the different muscle structures, an important parameter to identify mobility dysfunctions. Regarding the specific training for the use of RUSI method, the literature suggests that a physiotherapist new to ultrasound imaging should perform adequate training for the use of the ultrasound machine and should be able to extrapolate

from the ultrasound image the static and dynamic morphology of the myofascial structures, before using it in clinical rehabilitation practice. Protocols have been published on the use of RUSI to evaluate the paraspinal, abdominal and pelvic floor muscles to help the physiotherapist¹.

The RUSI can be a new method with a high clinical potential as a SUPPORT to the physiotherapist only for their own skills and NOT used for DIAGNOSTIC PURPOSES. However, the topic does not seem to be completely exhausted and the debate in the scientific community could provide important contributions.

CONCLUSION

Despite the growing scientific evidence on the use of RUSI, several questions remain. Future research should define more in detail the potential and limits of its use as well as the acquisition of skills, still unclear due to the lack of shared and well-structured training processes in line with current legislative regulations.

The lack of a gold standard that allows to define the degree of accuracy in the static and dynamic assessment of the ultrasound images of the myofascial system, as well as its use in the form of biofeedback for treatment, makes it difficult to standardize some procedures. These aspects lead us to be still cautious in transferring the evidence reported in the literature to the rehabilitation clinic. The potential confusions concern the areas of practical application, which can be overcome through the drafting of guidelines or common clinical care good practices and the improvement of training strategies for its use. Future research is warranted to build high quality studies, to indicate greater methodological rigor given the basis of promising works already present in the literature.

ACKNOWLEDGEMENTS

The authors would like to thank to Andrea Pittola, Laura Valloni, Nicola Ciampica, Sara Sisani for the translation of this paper.

REFERENCES

1. Whittaker, J. L. *et al.* Rehabilitative ultrasound imaging: understanding the technology and its applications. *J. Orthop. Sports Phys. Ther.* **37**, 434–449 (2007).
2. O’Sullivan, C., Meaney, J., Boyle, G., Gormley, J. & Stokes, M. The validity of Rehabilitative Ultrasound Imaging for measurement of trapezius muscle thickness. *Man. Ther.* **14**, 572–578 (2009).
3. Hebert, J. J., Koppenhaver, S. L., Parent, E. C. & Fritz, J. M. A systematic review of the reliability of rehabilitative ultrasound imaging for the quantitative assessment of the abdominal and lumbar trunk muscles. *Spine (Phila. Pa. 1976)*. **34**, E848 (2009).
4. Lin YJ *et al.* Reliability of thickness measurements of the dorsal muscles of the upper cervical spine: an ultrasonographic study. *J Orthop Sports Phys Ther*, **39**, 850-7 (2009).
5. Teyhen, D. S. *et al.* Ultrasound Characteristics of the Deep Abdominal Muscles During the Active Straight Leg Raise Test. *Arch. Phys. Med. Rehabil.* **90**, 761–767 (2009).
6. Bentman, S., O’Sullivan, C. & Stokes, M. Thickness of the middle trapezius muscle measured by rehabilitative ultrasound imaging: Description of the technique and reliability study. *Clin. Physiol. Funct. Imaging* **30**, 426–431 (2010).
7. Day, J. M. & Uhl, T. Thickness of the lower trapezius and serratus anterior using ultrasound imaging during a repeated arm lifting task. *Man. Ther.* **18**, 588–593 (2013).
8. McGaugh J *et al.* Intrasession and interrater reliability of rehabilitative ultrasound imaging measures of the deep neck flexors: A pilot study. *Physiother Theory Pract.* **27**, 572-7 (2011).
9. Talbott, N. R. & Witt, D. W. Ultrasound imaging of the serratus anterior muscle at rest and during contraction. *Clin. Physiol. Funct. Imaging* **33**, 192–200 (2013).
10. Wong, A. Y. L., Parent, E. & Kawchuk, G. Reliability of 2 ultrasonic imaging analysis methods in quantifying lumbar multifidus thickness. *J. Orthop. Sports Phys. Ther.* **43**, 251–262 (2013).
11. Schneebeli, A., Egloff, M., Giampietro, A., Clijsen, R. & Barbero, M. Rehabilitative ultrasound imaging of the supraspinatus muscle: Intra- and interrater reliability of thickness and cross-sectional area. *J. Bodyw. Mov. Ther.* **18**, 266–272 (2014).
12. Temes, W. C. *et al.* Reliability and validity of thickness measurements of the supraspinatus muscle of the shoulder: an ultrasonography study. *J. Sport Rehabil.* **Technical**, 1–5 (2014).
13. Sions, J. M., Velasco, T. O., Teyhen, D. S. & Hicks, G. E. Ultrasound imaging: Intraexaminer and interexaminer reliability for multifidus muscle thickness assessment in adults aged 60 to 85 years versus younger adults. *J. Orthop. Sports Phys. Ther.* **44**, 425–434 (2014).
14. Manuscript, A. Multifidi Thickness in Older Adults with Chronic Low Back Pain. **38**, 33–39 (2016).
15. Jeong, J. R., Ko, Y. J., Ha, H. G. & Lee, W. H. Reliability of rehabilitative ultrasonographic imaging for muscle thickness measurement of the rhomboid major. *Clin. Physiol. Funct. Imaging* **36**, 134–138 (2016).
16. Lee, N. G. *et al.* Novel augmented ADIM training using ultrasound imaging and electromyography in adults with core instability. *J. Back Musculoskelet. Rehabil.* **24**, 233–240 (2011).

17. Painter, E. E., Ogle, M. D. & Teyhen, D. S. Lumbopelvic dysfunction and stress urinary incontinence: A case report applying rehabilitative ultrasound imaging. *J. Orthop. Sports Phys. Ther.* **37**, 499–504 (2007).
18. Teyhen, D. S. *et al.* Rehabilitative ultrasound imaging of the abdominal muscles. *J. Orthop. Sports Phys. Ther.* **37**, 450–466 (2007).
19. Kiesel, K. B., Uhl, T., Underwood, F. B. & Nitz, A. J. Rehabilitative ultrasound measurement of select trunk muscle activation during induced pain. *Man. Ther.* **13**, 132–138 (2008).
20. Kiesel, K. B., Uhl, T. L., Underwood, F. B., Rodd, D. W. & Nitz, A. J. Measurement of lumbar multifidus muscle contraction with rehabilitative ultrasound imaging. *Man. Ther.* **12**, 161–166 (2007).
21. Hides, J. A., Stanton, W., McMahon, S., Sims, K. & Richardson, C. Effect of stabilization training on multifidus muscle cross-sectional area among young elite cricketers with low back pain. *J. Orthop. Sports Phys. Ther.* **38**, 101–108 (2008).
22. Pressler, J. F., Heiss, D. G., Buford, J. A. & Chidley, J. V. Between-day repeatability and symmetry of multifidus cross-sectional area measured using ultrasound imaging. *J. Orthop. Sports Phys. Ther.* **36**, 10–18 (2006).
23. Brenner, A. K., Gill, N. W., Buscema, C. J. & Kiesel, K. Improved activation of lumbar multifidus following spinal manipulation: A case report applying rehabilitative ultrasound imaging. *J. Orthop. Sports Phys. Ther.* **37**, 613–619 (2007).
24. Hides, J. A., Miokovic, T., Belavý, D. L., Stanton, W. R. & Richardson, C. A. Ultrasound imaging assessment of abdominal muscle function during drawing-in of the abdominal wall: An intrarater reliability study. *J. Orthop. Sports Phys. Ther.* **37**, 480–486 (2007).
25. Raney, N. H. Observed Changes in Lateral Abdominal Muscle Thickness After Spinal Manipulation: A Case Series Using Rehabilitative Ultrasound Imaging. **37**, 472–479 (2007).
26. Herbert, W. J., Heiss, D. G. & Basso, D. M. Influence of feedback schedule in motor performance and learning of a lumbar multifidus muscle task using rehabilitative ultrasound imaging: A randomized clinical trial. *Phys. Ther.* **88**, 261–269 (2008).
27. Sweeney, N., O’Sullivan, C. & Kelly, G. Multifidus muscle size and percentage thickness changes among patients with unilateral chronic low back pain (CLBP) and healthy controls in prone and standing. *Man. Ther.* **19**, 433–439 (2014).
28. Hosseinfar, M., Akbari, A. & Ghiasi, F. Intra-Rater Reliability of Rehabilitative Ultrasound Imaging for Multifidus Muscles Thickness and Cross Section Area in Healthy Subjects. *Glob. J. Health Sci.* **7**, 354–361 (2015).
29. Jopowicz, R., Jopowicz, M., Czarnocki, L., Deszczyński, J. M. & Deszczyński, J. Current Uses of Ultrasound Imaging in Musculoskeletal Rehabilitation. *Ortop. Traumatol. Rehabil.* **19**, 0–0 (2017).
30. Fernández-Lao, C. *et al.* The effectiveness of a mobile application for the development of palpation and ultrasound imaging skills to supplement the traditional learning of physiotherapy students. *BMC Med. Educ.* **16**, 1–8 (2016).
31. Collebrusco, L., Lombardini, R. & Censi, G. The Use of Ultrasound Images in Manual Therapy and Additionally in Assessment of Shoulder Impingement Syndrome. *Open J. Ther. Rehabil.* **05**, 53–70 (2017).
32. la rusi, L., Palmieri, L., Censi, G. & Lombardini, R. Lumbar Stenosis of the Aging Spine: Evaluation and Treatment According to the Evidence Based Medicine for the Improvement of the Quality of Life. *Open J. Ther. Rehabil.* **05**, 36–42 (2017).
33. Doorbar-Baptist S *et al.* Ultrasound-based motor control training for the pelvic floor pre- and post-prostatectomy: Scoring reliability and skill acquisition. *Physiother Theory Pract.* **33**, 296–302 (2017).
34. Gray JM *et al.* Integrating Musculoskeletal Sonography Into Rehabilitation: Therapists’ Experiences With Training and Implementation. *OTJR (Thorofare N J)*. **37**, 40–49. (2017).
35. Hayward, S. A. & Janssen, J. Use of thoracic ultrasound by physiotherapists: a scoping review of the literature. *Physiother. (United Kingdom)* **104**, 367–375 (2018).
36. Calvo-Lobo, C. *et al.* Ultrasonography comparison of diaphragm thickness and excursion between athletes with and without lumbopelvic pain. *Phys. Ther. Sport* **37**, 128–137 (2019).
37. Abuín-Porras, V. *et al.* Comparison of lateral abdominal musculature activation during expiration with an expiratory flow control device versus the abdominal drawing-in maneuver in healthy women: A cross-sectional observational pilot study. *Med.* **56**, (2020).
38. Teyhen, D. S. Rehabilitative ultrasound imaging for assessment and treatment of musculoskeletal conditions. *Man. Ther.* **16**, 44–45 (2011).