

NEUROIMAGING OF INTRACRANIAL STENOSIS

Coda Marco¹, Aliberti Daniele¹, Esposito Ilaria², Romano Daniele Giuseppe³

¹Dott. A.O.U. "San Giovanni di Dio e Ruggi d'Aragona Salerno"

²Dott.ssa TSRM

³Dott. Dirigente Medico - A.O.U. "San Giovanni di Dio e Ruggi d'Aragona Salerno"

KEYWORDS: Cerebral Hyperperfusion Syndrome, STENT, PCASL Sequence

ABSTRACT

Cerebral hyperperfusion syndrome is a potential complication after intracranial angioplasty or stenting and ASL imaging could be used to predict and diagnose hyperperfusion syndrome and contribute to reduce its complications, making it possible to better manage patients undergoing endovascular treatment.

INTRODUCTION

Stenosis of the cerebral vessels is a pathology characterized by narrowing of the lumen of the blood vessels can lead to serious consequences such as stroke, cerebral hemorrhage and death. Endovascular treatment with stents is increasingly used in selected patients and a potential complication of this treatment is cerebral hyperperfusion syndrome. It is possible to predict and diagnose hyperperfusion syndrome with the Pseudo-Continuous Arterial Spin Labelling (pCASL) perfusion sequence. For this purpose we report a case of a 63-year-old man with an hyperperfusion syndrome after percutaneous angioplasty and stenting of a right internal carotid artery syphon stenosis documented with ASL imaging.

MATERIALS AND METHODS

At the San Giovanni di Dio and Ruggi d'Aragona hospital we use Siemens Skyra multiparametric magnetic resonance equipment with 3 Tesla static magnetic field, with 16-channel Phased-Array head neck coil. The study protocol involves the use of the pCASL sequence, pre and post endovascular treatment and stenting of intracranial arterial stenosis. The ASL sequence is a technique that doesn't use exogenous contrast agent, but it uses a technique of "marking" the proton spin of the water contained in the blood to identify the movement, and therefore the flow, within the vessels. To do this, we work on the longitudinal magnetization of water, in order to make it different from other tissues. The protons so marked constitute a tracer for perfusion, they spread from the capillaries to the tissues, allowing a quantitative measurement of the cerebral blood flow (CBF). In particular, the pCASL sequence uses a train of short RF pulses to perform spin inversion, in conjunction with a synchronous field gradient, which performs a flow-driven adiabatic inversion as the blood flows through the marking plane.

The FOV must cover the entire area of interest, the coverage of the area of interest is obtained with about 40 slices with a thickness of 3 mm and with a gap, in our case, of 50%. Axial scanning planes are obtained by placing the first layer at the level of the occipital foramen and the last at the level of the vertex, on the axial reference plane, it is necessary to verify that the

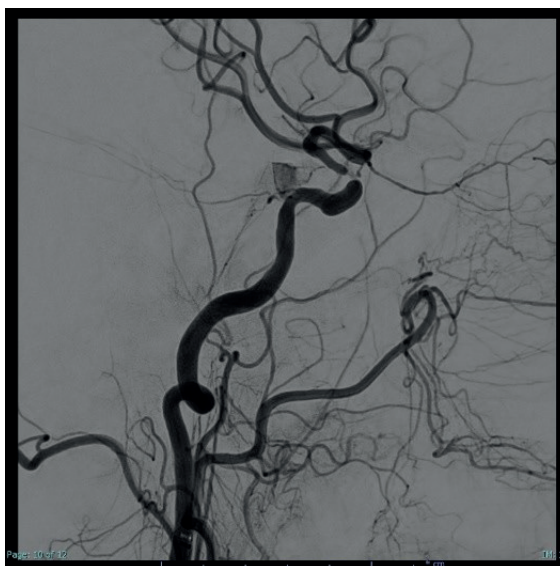


Fig. 1 - Pre-treatment angiography

scanning covers the area of interest; on the coronal reference plane, the layers shall be perpendicular to the median sagittal plane and the laterolateral position shall be verified; on the sagittal reference plane, oblique the layer parallel to the bicommissural or Talairach line, that line passes through the front and rear white commissure and the anteroposterior position shall be verified; The phase coding direction is LL and the pre-saturation band is higher.

The echo time used in our case was about 16 ms, while the repetition time about 5000 ms.

Our case concerns a 63-year-old man presented to our emergency department with acute neurological syndrome characterized by left leg paresis from one week and right hemiparesis from two months. A unenhanced CT scan showed focal subacute ischemic lesions of the white matter of the semioval centers and the right cortical- subcortical frontal region (Figure 1).

At the Angio-CT, both cervical and petrose internal carotids arteries (ICAs) were thin, with chronic occlusion of left ICA and hemodynamically significant stenosis in the right ICA ophthalmic tract. A subsequent brain MR confirmed subacute ischemic lesions and Pseudo

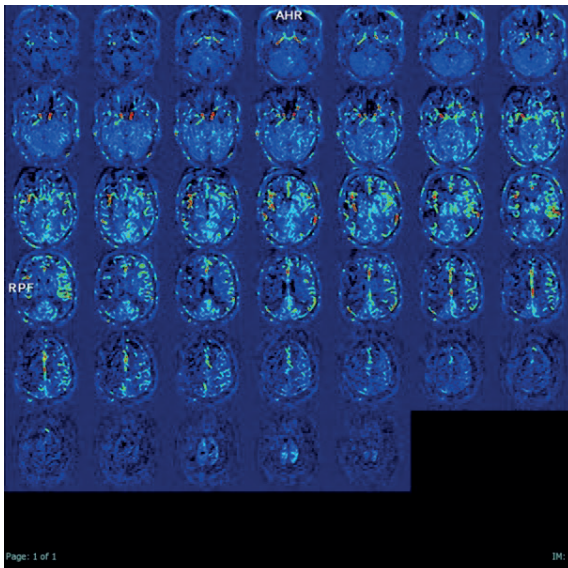


Fig. 2 - Pre- treatment pCASL sequence

Continuous Arterial Spin Labeling (pCASL) sequence documented a reduction of the cerebral blood flow (CBF) in the right brain hemisphere (Figure 2).

A dual antiplatelet therapy (DAPT) with Aspirine 100 mg and Clopidogrel 75 mg and hypolipemic therapy with Atorvastatin 40 mg were started. After one week, under general anesthesia, a percutaneous angioplasty (PTA) and stenting of the intracranial right ICA stenosis (Neurospeed 2.5x8 mm and Credo 4x15 mm, Acanadis GmbH, Pforzheim, Germany) was done obtaining the dilatation of the stenotic segment and restoring a normal blood flow for the right MCA territories (Figure 3).

At the end of the procedure, coming off anesthesia, the patient exhibited seizures and breathing failure. He was re-intubated and mechanically ventilated. A unenhanced CT scan did not show procedural complications. A subsequent MRI showed no parenchymal damage, with hyperperfusion of the cerebral cortex in the right insular and parietal location, evident in the ASL sequence (Figure 4).

He was slowly awakened with a strict control of blood pressure (BP) and intravenous mannitol was added to

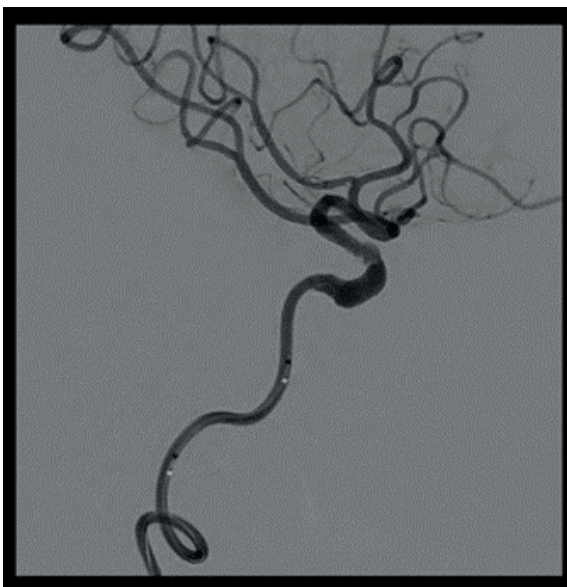

Fig. 3 - Post.treatment angiography

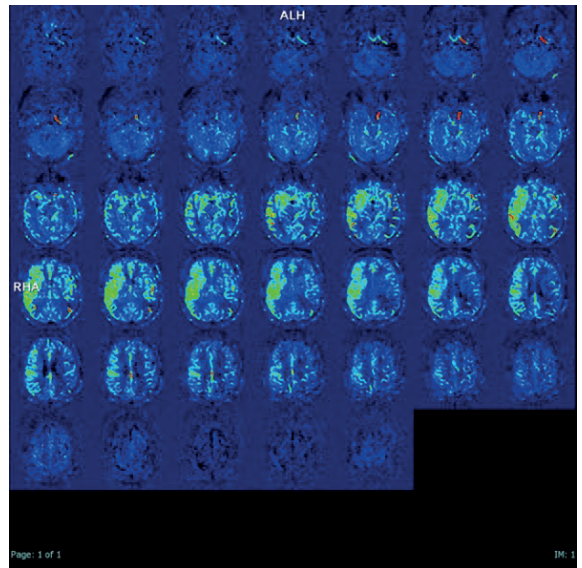


Fig. 4 - pCASL sequence with hyperperfusion

his therapy. During the following week patient presented fluctuating cognitive impairments and right arm paresis. Another pCASL study documented a slight reduction of the right hemispheric hyperperfusion.

In the literature, hyperperfusion syndrome has been reported in 12 cases (Table 1), with symptoms characterized by headache, seizures, focal neurological deficit or intracerebral hemorrhage. Nine patients had middle cerebral artery stenosis, five vertebral artery stenosis, four intracranial ICA stenosis, and one basilar artery stenosis.

Our case had focal neurological deficits related to hyperperfusion of the right middle cerebral artery. In 17 cases, and in all cases of ICA stenosis, hyperperfusion syndrome was complicated by intracerebral hemorrhage. To our knowledge this is the first reported case of hyperperfusion syndrome after intracranial ICA stenosis uncomplicated by cerebral hemorrhage. In all reported cases the preoperative degree of stenosis was more than 60% and they had poor collateral circulation detected with neuroimaging techniques. In our case, there was 90% intracranial ICA stenosis with slow leptomeningeal collateral circulation from the right posterior cerebral artery.

To our knowledge this is the first case of cerebral hyperperfusion syndrome documented with the pCASL sequence. The pCASL imaging has been previously studied in stroke patients and compared with the bolus Perfusion Weight Imaging (PWI), showing potential advantages such as shorter acquisition and reconstruction time and no needs of motion correction. Moreover ASL imaging has the ability to identify bilateral disease, since it can be used in quantitative rather than qualitative manner, and the ability to detect more subtle perfusion alterations compared with bolus PWI. Since has been documented in ASL imaging the arterial transit artifact (ATA), that represent a longer arterial arrival time in hypoperfused territories due to collateral circulation, ASL has been used to identify and grade collateral circulation in patients with occlusive cerebrovascular diseases, such as intracranial arterial stenosis¹⁰ or Moya-Moya disease. In our case we noticed in the pCASL pre-treatment the ATA in the pre-stenotic portion of the right ICA, disappearing in pCASL post-treatment. To our knowledge this “slow flow sign” has never been documented before and to our opinion can be a useful

STUDY AND YEAR	N. OF PATIENTS	STENOSIS LOCATION	TREATMENT TECHNIQUE	ANTICOAGULATION/ANTIAGGREGATION	HEMORRHAGE
Meyers et al., 2000 ³	1	Bilateral VA	Stenting	DAPT	No
Bando et al., 2001 ⁷	1	VA	PTA	Heparine	No
Liu et al., 2001 ⁸	1	MCA	PTA	Heparine	Yes
Qureshi et al., 2002 ⁹	3	1 ICA / 2 MCA	Stenting	DAPT	Yes
Garcia-Bargo et al., 2004 ¹⁰	1	ICA	Stenting	DAPT	Yes
Rezende et al., 2006 ¹¹	1	VA	Stenting	Clopidogrel	Yes
Terata et al., 2006 ¹²	2	ICA / VA	PTA / Stenting	DAPT	Yes
Jiang et al., 2007 ¹³	1	VA	Stenting	DAPT	Yes
Zhang et al., 2009 ¹⁴	1	VA	Stenting	DAPT	Yes
Wolfe et al., 2009 ¹⁵	1	MCA	Stenting	DAPT	No
Xu et al., 2014 ¹⁶	6	5 MCA / 1 BA	Stenting	DAPT	Yes
Mondel et al., 2014 ¹⁵	1	ICA	Stenting	DAPT	Yes

Tab. 1 - BA: basic artery; DAPT: double antiplatelet therapy; ICA: internal carotid artery; MCA: medium carotid artery; PTA: percutaneous angioplasty; VA: vertebral artery

marker for intracranial stenosis.

CONCLUSION

Endovascular treatment with stent is increasingly used; in case of endovascular treatment there is always to be considered of hyperperfusion syndrome, as a potential consequence. The incidence of hyperperfusion syndrome is about 2.2% and the incidence of intracranial hemorrhage, complication of hyperperfusion syndrome, is about 0.8%. Although the incidence of intracerebral hemorrhage caused by cerebral hyperperfusion syndrome is low, mortality and the rate of severe disability are extremely high.

The study focused on the use of ASL imaging in clinical practice, before and after endovascular treatment and stenting of intracranial stenosis, to predict and diagnose hyperperfusion syndrome. In particular, in our case it was reported the presence of the arterial transit artifact (ATA) before treatment, no longer present after treatment of stenosis. This artifact could be a useful indicator for intracranial stenosis. The introduction of this sequence accompanied with a monitoring of blood pressure could avoid the occurrence of complications associated with hyperperfusion syndrome, with results of complete or semi-complete recovery and a reduction in mortality rate.

REFERENCES

- CORIASCO M., RAMPADO O., BRADAC G., *Elementi di risonanza magnetica*, Springer, Milano, 2014, p.135
- GRADE M., HERNANDEZ TEMAMES J.A., PIZZINI F.B., ACHTEN E., GOLAY X., SMITS M., "A neuroradiologist's guide to arterial spin labeling MRI in clinical practice", *Neuroradiology*, 2015
- ABOU-CHEBL A. et al., *Intracranial hemorrhage and hyperperfusion syndrome following carotid artery stenting: risk factors, prevention, and treatment*, *J. Am. Coll. Cardiol.* 43, 1596–1601 (2004).
- COUTTS S. B., HILL M. D. & Hu, W. Y., *Hyperperfusion syndrome: toward a stricter definition*, *Neurosurgery* 53, 1053–58; discussion 1058 (2003).
- MEYERS P. M., PHATOUROS C. C. & HIGASHIDA R. T., *Hyperperfusion syndrome after intracranial angioplasty and stent placement*, *Stroke* 37, 2210–2211 (2006).
- OGASAWARA K. et al., *Intracranial hemorrhage associated with cerebral hyperperfusion syndrome following carotid endarterectomy and carotid artery stenting: retrospective review of 4494 patients*, *J. Neurosurg.* 107, 1130–1136 (2007).
- TAKAYAMA K. et al., *Cerebral hemorrhage with angiographic extravasation immediately after carotid artery stenting*, *Radiat Med* 25, 359–363 (2007).
- ZAHAECHUK G., *Arterial spin label imaging of acute ischemic stroke and transient ischemic attack*, *Neuroimaging Clin. N. Am.* 21, 285–301, x (2011).
- DETRE J. A. & ALSOP D. C., *Perfusion magnetic resonance imaging with continuous arterial spin labeling: methods and clinical applications in the central nervous system*, *Eur. J. Radiol.* 30, 115–124 (1999).61
- CHNG S. M. et al., *Territorial arterial spin labeling in the assessment of collateral circulation: comparison with digital subtraction angiography*, *Stroke* 39, 3248–3254 (2008).
- LIEBESKIND D. S., *Collateral circulation*, *Stroke* 34, 2279–2284 (2003).
- LOU X. et al., *Collateral perfusion using arterial spin labeling in symptomatic versus asymptomatic middle cerebral artery stenosis*, *J. Cereb. Blood Flow Metab.* 39, 108–117 (2019).
- ZAHARCHUK G. et al., *Arterial spin-labeling MRI can identify the presence and intensity of collateral perfusion in patients with moyamoya disease*, *Stroke* 42, 2485–2491 (2011).
- ZAHARCHUK G. et al., *Arterial spin-label imaging in patients with normal bolus perfusion-weighted MR imaging findings: pilot identification of the borderzone sign*, *Radiology* 252, 797–807 (2009).